

ULTRASONOGRAPHIC EVALUATION OF PREGNANCY WITH BLEEDING PER VAGINAAmit C. Shah¹, Tushar Patil²**HOW TO CITE THIS ARTICLE:**

Amit C. Shah, Tushar Patil. "Ultrasonographic Evaluation of Pregnancy with Bleeding Per Vagina". Journal of Evolution of Medical and Dental Sciences 2014; Vol. 3, Issue 72, December 22; Page: 15242-15265, DOI: 10.14260/jemds/2014/4052

ABSTRACT: This study of 150 patients presenting with bleeding per vagina in first, second & third trimester was conducted to evaluate the cause of bleeding, assess the severity of condition, to predict the later course of pregnancy & to evaluate the role of ultrasonography in management. This study was conducted in department of Radiology at Basaweshwar Teaching & General hospital, Government general hospital & Sangameshwar teaching & General hospital. This study concludes that, Ultrasonography should be the first line of investigation in all the cases of bleeding per vagina in pregnancy.

KEYWORDS: Ultrasonography, Bleed per vagina, Placenta previa, Abruptio Placenta, abortion, blighted ovum, missed abortion.

INTRODUCTION: During the past 25 years, extensive study has been done on ultrasonography. Today clinicians and imagiologists use ultrasonography to evaluate various abnormalities. Most of the times, the pelvic examination and laboratory tests remain obscure in diagnosing the cause of bleeding per vagina. The invent of ultrasound has, to a large extent met the requirement successfully. Imaging in the first trimester pregnancy has rapidly progressed over the past decade with development of transvaginal transducers, which allows the gravid uterus and adnexa to be visualized with great details. Trans-abdominal sonography allows visualization of larger field of anatomy.¹ Patients referred for first trimester evaluation often have vaginal bleeding, which raises the suspicion of an ectopic pregnancy or a threatened abortion. The primary goal of ultrasound evaluation in the first trimester, is to determine whether the pregnancy is intrauterine and whether the embryo is living.² Several studies have demonstrated that ultrasound at 16 to 18 weeks can identify these patients with greater risk for placenta previa and exclude the diagnosis in most of the cases.³ Many clinical problems are ascribed to placenta and sonography is the only non-invasive means of evaluating placenta.⁴

AIMS AND OBJECTIVES:

1. To evaluate the cause of bleeding per vagina in pregnancy of 1st, 2nd and 3rd Trimesters.
2. To assess the severity of the conditions.
3. To predict the later course of pregnancy in cases with bleeding occurring in first half of pregnancy.
4. To evaluate the role of ultrasound in management of bleeding per vagina in pregnancy.

MATERIALS AND METHODS: The present study was conducted in ultrasound room of the Department of Radiology at Basaveshwar Teaching & General Hospital, Government General Hospital and Sangameshwar Teaching & General Hospital, Gulbarga.

ORIGINAL ARTICLE

TYPE OF STUDY: Diagnostic test evaluation study.

SAMPLE SIZE: Present study is a prospective study of 150 cases.

SOURCE POPULATION: Patients from Basaveshwar Hospital, Government General Hospital and Sangameshwar Hospital, Gulbarga presenting with bleeding per vagina in pregnancy were selected.

INCLUSION CRITERIA:

1. All patients presenting with clinically suspected placental causes of bleeding per vagina.
2. All patients of clinically suspected ectopic pregnancy.
3. All patients of clinically suspected hydatidiform mole.
4. All patients of clinically suspected abortions.

EXCLUSION CRITERIA:

1. All patients with gynecological causes of bleeding per vagina in pregnancy.
2. All patients with bleeding per vagina in pregnancy due to systemic causes of bleeding.

DIFFERENT CRITERIA USED IN SONOLOGICAL DIAGNOSIS: Ultrasonographic features specific to different causes of bleeding per vagina in pregnancy will be used as parameter to compare.

THE COURSE OF PREGNANCY IS DIVIDED INTO⁵:

- First trimester First 12 weeks.
- Second trimester 13-29 weeks.
- Third trimester 29-40 weeks.

ABORTION: Termination of pregnancy before the period of viability, which is considered to occur at 28 weeks.⁶

BLIGHTED OVUM:⁷

1. Irregular gestational sac without evidence of fetal pole.
2. Mean sac diameter (MSD) of 25mm transabdominally. MSD of 16mm.
3. MSD of 20mm transabdominally without evidence of yolk sac.

MISSED ABORTION⁷:

1. Fetus identified without cardiac activity, in the gestational sac.
2. MSD is small for gestational age.
3. Enlarged placenta with hydropic changes may be present.

COMPLETE ABORTION⁷:

1. Enlarged uterus.
2. No evidence of gestational sac or fetus.
3. Thickened endometrial core with or without fluid.

INCOMPLETE ABORTION⁷:

1. Enlarged uterus.
2. Empty ill-defined gestational sac may be present.
3. A sac with internal echoes, which are not clearly fetal, they might be part of fetus or placenta or blood.

THREATENED ABORTION⁷:

1. Internal os is closed.
2. Fetal cardiac activity is normal, but the patient has bleeding per vagina.
3. Evidence of perisac bleed may or may not be present.

INEVITABLE ABORTION⁷:

1. Evidence of fetal cardiac activity.
2. Low placed sac.
3. Open internal Os.

SEPTIC ABORTION⁷: When the infected dead fetus or retained products are found in uterine cavity.

PLACENTA PREVIA⁸:

1. When the placenta is covering the internal os completely, it is termed as complete placenta previa.
2. When the placental margin encroaches the tip of internal Os, it is termed marginal placenta previa.
3. When placental tip lies within 2cms from internal os, it is termed low lying placenta.

ABRUPTION PLACENTA⁸: When there is premature separation of normally implanted placenta, It is termed abruptio placenta. When the retroplacenta hypoechoec area is more than 3cms and shows evidence of dot it is termed retroplacental hemorrhage. Abruptio placenta is equivalent to retroplacental hemorrhage on ultrasound, but all cases of abruptio do not demonstrate hemorrhage.

HYDATIDIFORM MOLE:

COMPLETE⁸:

1. Generalized swelling of the villous tissue.
2. Diffused trophoblastic hyperplasia without embryonic or fetal tissue.
3. Without differentiation of placenta.

PARTIAL⁹:

1. Greatly enlarged placenta relative to the size of uterine cavity.
2. Cystic spaces within placenta 'molar placenta" which may not always be present.
3. An amniotic cavity (gestational sac), either empty or containing amorphous fetal echoes.
4. A well-formed but growth-retarded fetus, either dead or alive.

ORIGINAL ARTICLE

ECTOPIC PREGNANCY¹⁰: When there is evidence & gestational sac with or without fetal pole, outside the uterine cavity, it is termed as ectopic pregnancy.

METHODS: Ultrasound examination was performed with real-time gray scale unit (Ultramark IV All, USA in Basaveshwar & Sangameshwar Hospital and HDI 1500, AU USA In Government General Hospital) transabdominal ultrasound was performed In all patients. Transvaginal ultrasound was done In these patients In whom transabdominal ultrasound provided no conclusive diagnosis. For transabdominal ultrasound, 3.5 MHz transducer was used and for trans-vaginal sonography 5 to 9 MHz transducer was used.

Patients were asked to lie down in supine position. Patient's abdomen was exposed. After application of coupling medium, the transducer was placed over the area to be examined. Longitudinal and transverse scans were performed over lower abdomen. In early pregnancy, the full bladder technique was adopted for better visualization of uterus, when transabdominal scan was performed. In late pregnancy the scan was performed on the distended abdomen for visualization of fetal cardiac activity, placental position, retroplacental area and internal os.

TRANSVAGINAL ULTRASOUND WAS PERFORMED WHEN:

- a) Fetal cardiac activity was not evident on transabdominal scan.
- b) Intrauterine sac was not identified on transabdominal scan in patients with clinical suspicion of ectopic pregnancy.
- c) The adnexa were not satisfactorily visualized on transabdominal scan in patients with clinically suspected ectopic pregnancy.
- d) When placental margin was not satisfactorily seen in relation to internal os, on transabdominal scan.

The follow-up ultrasound examination was done in future course of pregnancy, in patients with placenta previa detected in second trimester and in patients with retroplacental hemorrhage or abruptio placenta detected in second trimester.

The interval between the subsequent serial scans depended on the severity of condition, some were followed up for every week and some were followed up after 4 to 6 weeks.

OBSERVATION:

| Clinical Condition | No. of Patients | Maternal Age Range | Gestational Age Range | Percent |
|----------------------|-----------------|--------------------|-----------------------|---------------|
| Spontaneous abortion | 105 | 18-35 | 7-27 | 70.00 |
| Hydatidiform mole | 04 | 20-28 | 10-21 | 2.67 |
| Placenta previa | 22 | 18-36 | 11-35 | 14.67 |
| Abruptio placenta | 09 | 26-40 | 18-36 | 6.00 |
| Ectopic pregnancy | 10 | 22-32 | 10-11 | 6.66 |
| Total | 150 | | | 100.00 |

Table 1: Conditions with bleeding per vagina

Out of 150 cases in the present study, maximum cases i.e. 105 (70%) were of spontaneous abortion, followed by placenta previa 22 cases (14.67%).

ORIGINAL ARTICLE

| Age Group (Years) | No. of Cases | Percentage |
|-------------------|--------------|---------------|
| 16-20 | 23 | 15.33 |
| 21-25 | 61 | 40.67 |
| 26-30 | 53 | 35.33 |
| 31-35 | 10 | 6.67 |
| 36-40 | 03 | 2.00 |
| Total | 150 | 100.00 |

Table 2: Maternal Age distribution

In the present study, the youngest patient was 17 years and the oldest patient of 37 years. Maximum number of patients noticed in the age group of 21 to 25 years (61 cases) followed by 26-30 years (53 cases).

| Gestational Age | No. of Cases | Percentage |
|--|--------------|---------------|
| 1 st Trimester (0-12 weeks) | 91 | 60.67 |
| 2 nd Trimester (13-28 weeks) | 52 | 34.66 |
| 3 rd Trimester (29-40 weeks) | 07 | 4.7 |
| Total | 150 | 100.00 |

Table 3: Gestational Age Distribution

In this study conducted, the minimum gestational age when patient presented with PV bleeding was 7 weeks and maximum was 36 weeks. Maximum number of patients presented with PV bleeding in 1st trimester 91 cases (60.67%) followed by 2nd trimester 52 cases (34.66%) and 3rd trimester 7 (4.7%).

| Types of Abortion | No. of Cases | Percentage |
|---------------------|--------------|---------------|
| Blighted Ovum | 16 | 15.24 |
| Threatened Abortion | 05 | 4.67 |
| Missed Abortion | 39 | 37.14 |
| Inevitable Abortion | 04 | 3.81 |
| Incomplete Abortion | 33 | 31.42 |
| Complete Abortion | 08 | 7.62 |
| Total | 150 | 100.00 |

Table 4: Types of Abortion

The maximum cases are of missed abortion i.e. 39(37.14%), followed by incomplete abortion i.e. 33(31.4%), blighted ovum 16 (15.24%), complete abortion 8(7.62%), threatened abortions (4.67%), inevitable abortion 4(3.81%).

ORIGINAL ARTICLE

| Condition | No. of Cases | Percentage |
|-------------------|--------------|---------------|
| Abortion | 80 | 87.91 |
| Ectopic Pregnancy | 10 | 10.98 |
| Hydatidiform Mole | 01 | 1.10 |
| Total | 150 | 100.00 |

Table 5: Condition presenting with bleeding per vagina in first Trimester

The maximum cases presenting with bleeding per vagina in first trimester were of abortion, 80 cases (87.91%) followed by ectopic pregnancy 10 cases (10.98%) and hydatidiform mole 1 (1.10%).

| Condition | No. of Cases | Percentage |
|--------------------|--------------|---------------|
| Hydatidiform | 03 | 5.77 |
| Abortion | 25 | 48.07 |
| Placenta Previa | 18 | 34.66 |
| Abruption Placenta | 06 | 11.54 |
| Total | 150 | 100.00 |

Table 6: Condition presenting with bleeding per vagina in Second Trimester

In second trimester, maximum cases with PV bleeding were of abortion i.e. 25 (48.07%), followed by placenta previa 18 (34.66%), abruptio placenta 6 (11.54%) and hydatidiform mole 3 (5.77%).

| Condition | No. of Cases | Percentage |
|--------------------|--------------|---------------|
| Placenta Previa | 04 | 57.14 |
| Abruption Placenta | 03 | 42.86 |
| Total | 07 | 100.00 |

Table 7: Conditions presenting with bleeding per vagina in third trimester

In third trimester, maximum cases with per vagina bleeding were of placenta previa i.e. 4 (57.14%), followed by abruptio placenta i.e. 3 (42.86%).

| Types of Placenta Previa | No. of Cases | Percentage |
|---------------------------|--------------|---------------|
| Low Lying Placenta Previa | 02 | 9.10 |
| Complete Placenta Previa | 03 | 13.63 |
| Partial Placenta Previa | 17 | 77.27 |
| Total | 22 | 100.00 |

Table 8: Types of placenta previa

In the present study, out of 22 cases of placenta previa, 17 cases (77.27%) were of partial placenta previa followed by 3 cases (13.63%) of complete placenta previa (13.63%), 2 cases (9.10%) of low lying placenta previa.

ORIGINAL ARTICLE

| Condition | Gestational Age | |
|---------------------------|---------------------------|---------------------------|
| | 2 nd Trimester | 3 rd Trimester |
| Low Lying Placenta Previa | 00 | 02 |
| Partial Placenta Previa | 17 | 00 |
| Complete Placenta Previa | 01 | 02 |
| Total | 18 | 04 |

Table 9: Types of placenta previa in relation to gestational age

In the present study, there are 17 cases of partial placenta previa and 1 case of complete placenta previa in 2 trimester and 2 cases of low lying placenta previa and 2 cases of complete placenta previa in 3rd trimester.

| Condition | No. of Cases | Percentage |
|----------------------------|--------------|---------------|
| Partial Hydatidiform Mole | 03 | 75.00 |
| Complete Hydatidiform Mole | 01 | 25.00 |
| Total | 04 | 100.00 |

Table 10: Types of Molar Pregnancy

Four cases of molar pregnancy were found, of which 3 were partial and 1 was complete.

| Condition | Gestational Age | |
|----------------------------|---------------------------|---------------------------|
| | 1 st Trimester | 2 nd Trimester |
| Partial Hydatidiform Mole | 00 | 03 |
| Complete Hydatidiform Mole | 01 | 00 |
| Total | 01 | 03 |

Table 11: Types of Molar Pregnancy in relation to Gestational Age

Out of 150 cases encountered, 1 was of complete hydatidiform mole in first trimester and 3 were of partial hydatidiform mole in second trimester.

| Clinical Condition | Transvaginal Sonography | Transabdominal Sonography | Total |
|--------------------|-------------------------|---------------------------|------------|
| Abortions | 24 | 81 | 105 |
| Hydatidiform Mole | 01 | 03 | 04 |
| Placenta Previa | 06 | 16 | 22 |
| Abruption Placenta | 00 | 09 | 09 |
| Ectopic Pregnancy | 07 | 00 | 07 |
| Total | 38 | 109 | 147 |

Table 12: Conditions diagnosed on Transvaginal and Transabdominal Sonography

ORIGINAL ARTICLE

Transvaginal sonography was done when transabdominal sonography did not provide conclusive diagnosis. In the present study, 41 cases required transvaginal sonography and in 38 cases diagnosis was concluded, 2 cases of ectopic pregnancy were inconclusive in diagnosis on transvaginal ultrasonography and in 1 case differential diagnosis of ovarian mass was given along with ectopic pregnancy, but laparoscopic surgery confirmed the presence of ectopic pregnancy.

DISCUSSION: Ultrasound is proved to be the most reliable diagnostic tool in assessing the abnormal conditions of pregnancy, which result in pregnancy failures. According to Duff GB et al ultrasound diagnosis of intrauterine pregnancy with fetal life signs and the pathological form was fully reliable after 9 weeks of gestation. They concluded that ultrasound is most reliable of all the tests.¹¹ According to the study of Robinson HP, if the menstrual history is correct it is possible to diagnose virtually all cases of blighted ovum, missed abortion, hydatidiform mole by single ultrasonographic examination. But in case of hydatidiform mole, there is only 98% reliability because a case of longstanding missed abortion undergoing hydropic change gives similar picture.¹² In predicting the continuation of pregnancy, ultrasound gives greater accuracy since it able to detect the fetal heart by scanning from 7 weeks onwards, Absent fetal heart signifies 100% unavoidable abortion. In the present study of 150 cases, maximum i.e. 105 cases (70%) were of spontaneous abortions, followed by placenta previa, 22 cases (14.76%), ectopic pregnancy in 10 cases (6.66%). In this study maximum number of patients was in between 21 to 30 years. In the present study, high incidence of abortions was noted with advanced maternal age (above 27 years) which was in comparison to study by Triolo et al, 1990.¹³ Maximum number of spontaneous abortions were seen in first trimester. Among spontaneous abortions, missed abortion was they commonest 39 cases (37.14%), which was in comparison with the study by Hamilton et al (1991).¹⁴ In the present study, 1 case (0.67%) of twin pregnancy was seen with one live and other dead fetus (missed abortion). Similar findings was seen in a study by Gerdts E (1999).¹⁵ 16 cases of blighted ovum were detected in study of 150 cases of bleeding per vagina in pregnancy with incidence of 15.24%, which was in line with the study of Goldstein SR. (1994). There were 5 cases of threatened abortion in present study (3.34%), two cases in first trimester and three cases in second trimester were detected. 2 of the 5 patients expelled dead fetus and remaining 3 cases (1 from first and 2 from second trimester) ended in full term normal delivery. 5 patients with clinical diagnosis of threatened abortion showed cardiac activity on ultrasound examination, internal os was closed and there was no evidence of perisac bleed. Gestational sac size was normal for gestational age. 2 cases aborted spontaneously.

Out of 33 cases of incomplete abortion observed in the present study, evidence of clusters of internal echoes were noted, internal os was open, thickened and irregular endometrium was noted and presence of fluid was commonly evident in uterine cavity. In 8 patients presenting with minimal bleeding per vagina in pregnancy in this study of 150 cases, had enlarged uterus without fetal pole or gestational sac, internal os was closed in most of the cases. Endometrial thickening was noted reflecting decidual reaction. Diagnosis of complete abortion was made in such cases.

39 cases of missed abortion were detected in present study, evidence of fetal pole without cardiac activity was commonest finding. Gestational sac size was small for gestational age. In 4 cases, when fetal (dead) was retained for a considerable amount of time, placental enlargement was evident.

4 cases of inevitable abortions were evident in the study. Low placed gestational sac with open internal os was noted in all cases, irregular gestational sac was noted in 1 case.

ORIGINAL ARTICLE

In this present study, 16 cases of blighted ovum were detected mean sac diameter (MSD) of more than 25 mm was noted in 10 cases, when scanned transabdominally. No evidence of fetal pole was noted. Sac was irregular in shape in 8 cases. Remaining 6 cases required transvaginal scan for diagnosis with MSD was more than 16 mm without evidence of fetal pole and 4 of these cases showed irregular sac. 4 cases of hydatidiform mole were detected in this study. 1 case of complete hydatidiform and 3 cases of partial hydatidiform mole. 3 cases including complete hydatidiform mole were detected by transabdominal Sonography and 1 case of partial hydatidiform were detected by transvaginal ultrasound. All the 4 patients with molar pregnancy were in between 20-30 years of age and 2 out of the 4 patients were primigravida (50%), which is exactly in line with the study done by Malhotra S (1989).

One case of complete hydatidiform mole showed enlarged uterus containing echogenic tissue with multiple cystic areas ranging between 0.7 to 2.0 cms. No evidence of fetal pole or placenta was seen. All the 3 cases of partial hydatidiform mole showed abnormally enlarged placenta with average measurement of 4.5 cms and multiple irregularly distributed cystic areas. Out of 3 cases of partial hydatidiform mole, 2 showed hydrocephalus with other anomalies and cardiac activity was not detected and in the other one case fetus was not detected.

In this study of 150 cases, 22 cases (14.67%) are of placenta previa, out of which 18 cases were detected in second trimester and 4 in third trimester. Out of 18 cases detected in second trimester, 17 were partial placental previa. 1 was of complete placenta previa. In these 18 cases, 15(83.33%) cases showed placental migration on follow-up. The follow-up scan was done at 34 weeks. 1 case of complete placenta previa and 2 cases of partial placenta previa had to undergo emergency surgery between 30 and 32 weeks. Follow-up ultrasound for these 3 cases was done before surgery and fetal cardiac activity was detected in all 3 cases. Out of 4 cases detected in third trimester, 1 case showed intrauterine death and other 3 had to undergo surgery.

| Author | Year | Percentage |
|--------------------|------|------------|
| MS Gilliesol et al | 1982 | 63.00 |
| Gallagher et al | 1987 | 92.15 |
| Ancona et al | 1990 | 80.00 |
| Lauria et al | 1996 | 86.00 |
| Taipale et al | 1997 | 95.00 |
| Present Study | 2003 | 83.33 |

Table 13: Placental Migration (Comparison with other studies)

Various authors studied the conversion rate of placenta previa detected in 2nd trimester to term. This present study shows conversion rate of 83.33% which correlates with study of other authors as shown in table-13. In the present study, 9 cases (6%) cases were of abruptio placenta. Retroplacental/ subchorionic hematoma with variable amount of placental, marginal separation was detected in cases. Six cases were detected in second trimester and three in third trimester. Unfavourable (IUD/ spontaneous abortion) outcome was detected on follow up scan in three cases (2 of third trimester and 1 of second trimester). 1 case of third trimester underwent emergency surgery, 4 cases of second trimester had normal delivery and 1 case of second trimester had spontaneous abortion.

ORIGINAL ARTICLE

The 4 cases of second trimester when progressed till term and delivered normally, had a clot volume of less than 55 ml. This finding in present study goes in correlation with authors findings in the table.

| Author | Year | Volume |
|---------------|------|---------|
| Sauerbrei | 1986 | < 60 ml |
| Nyberg | 1987 | < 60 ml |
| Present Study | 2003 | < 55 ml |

Table 14: Significance of clot volume in outcome of cases of abruptio placenta

In 4 cases which had unfavourable outcome, the clot volume measured between 55 and 95 ml. Overall outcome in 9 cases of abruptio placenta was favourable (FTND) in 5 cases (55.55%) and unfavourable (IUD and spontaneous) in 4 cases (44.44%). Variable amount of placental marginal separation was found in all 9 cases, but in cases with favourable outcome, separation was minimal and in cases with unfavourable outcome was considerable separation was found. These findings correlate with the study done by Nyberg DA (1987).

10 cases (6.66%) of ectopic pregnancies were found in this study of 150 cases. All the cases were detected in first trimester. Only 2 cases of ectopic pregnancy were detected with evidence of fetal cardiac activity. In 7 cases, non-cystic mass was detected and 1 case, a cystic mass was noted in adnexa. Fluid with internal echoes was noted in 6 of the 9 cases.

The present study corresponds with the study done by Romero R6° (1988) and Stabile I (1988).

7 cases out of 10 required transvaginal sonography for diagnosis as transabdominal sonography was non-conclusive. Neither of the two cases of live ectopic pregnancies were detected transabdominally. 2 cases of clinically suspected ectopic pregnancies were not diagnosed on ultrasound and 1 case was given a differential diagnosis of ovarian mass along with ectopic pregnancy, which was confirmed as ectopic pregnancy by laparoscopic surgery.

Out of 10 cases of ectopic pregnancy, ultrasound could diagnosis 7 cases (70%). This data corresponds to the study done by Piironen O (1981).

| Author | Year | Percentage |
|---------------|------|------------|
| Levi S | 1980 | 95.00 |
| Piironen | 1981 | 71.00 |
| Gleicher | 1983 | 89.00 |
| Dashefsky SM | 1988 | 60-83 |
| Present Study | 2003 | 70.00 |

Table 15: Accuracy of Ultrasonography in detection of Ectopic Pregnancy

SUMMARY: The present study comprised of 150 cases of bleeding per vagina in all the three trimesters of pregnancy:

1. All the cases underwent transabdominal sonography and transvaginal sonography was done when the diagnosis was inconclusive by transabdominal sonography.

ORIGINAL ARTICLE

2. Out of 150 cases, 105 were of spontaneous abortion, 22 of placenta previa, 10 of ectopic pregnancy, 9 of abruptio placenta and 4 of hydatidiform mole.
3. Maximum number of cases was in the age group of 21 to 30 years (76%).
4. Maximum number of cases (60.67%) presented in first trimester (0-12 weeks).
5. The abortions encountered in the present study are, threatened (5 cases), incomplete (33 cases), complete (8 cases), missed (39 cases), inevitable (4 cases) and blighted ovum (16 cases).
6. Commonest condition presenting with bleeding per vagina in first trimester is abortion, accounting to 87.91%.
7. Most common condition presenting with bleeding per vagina in second trimester was again abortion (48.07%).
8. Placenta previa (57.14%) was the commonest cause of bleeding per vagina in third trimester.
9. Among the types of placenta previa, partial placenta previa is most common (77.27%).
10. Maximum number of cases (17) of partial placenta previa presented during second trimester.
11. Among the types of molar pregnancy, incidence of partial hydatidiform mole was more common and most of the patients presented during second trimester.
12. Most of the cases (66.67%) with abruptio placenta presented with bleeding per vagina in second trimester.
13. All 10 cases of ectopic pregnancy presented in first trimester.
14. Ultrasonography was inconclusive in diagnosing 3 cases of ectopic pregnancies out of 10 cases.

CONCLUSION: The study entitled “Ultrasonographic Evaluation of Pregnancy with Bleeding Per Vagina” was conducted in the Department of Radiology, Government General Hospital, Basaveshwar Teaching & General Hospital, and Sangameshwar Hospital, Gulbarga.

THE CONCLUSIONS DRAWN FROM THE STUDY OF 150 CASES ARE AS FOLLOWS:

1. Ultrasonography is a valuable, non-invasive diagnostic aid in the cases presenting with bleeding per vagina in pregnancy.
2. Ultrasonography had high diagnostic value in detecting the causes of bleeding per vagina in pregnancy.
3. Ultrasonography can alter the course of management by assessing the severity of the condition.
4. Transvaginal ultrasonography provided conclusive diagnosis in cases where the diagnosis is inconclusive by transabdominal sonography.

Thus, the present study concludes that ultrasonography should be used as a first line investigation in all the cases of bleeding per vagina in pregnancy.

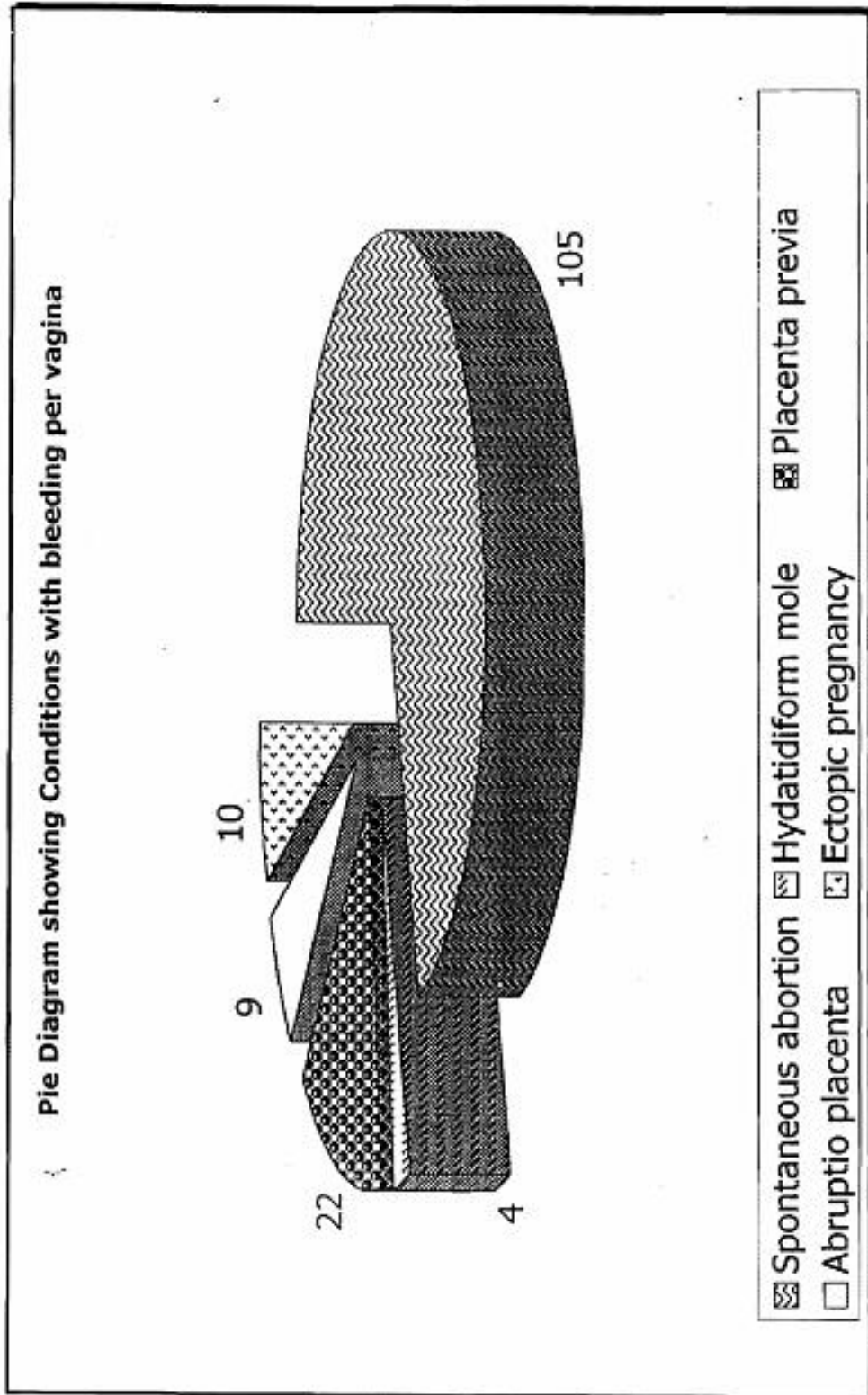
BIBLIOGRAPHY:

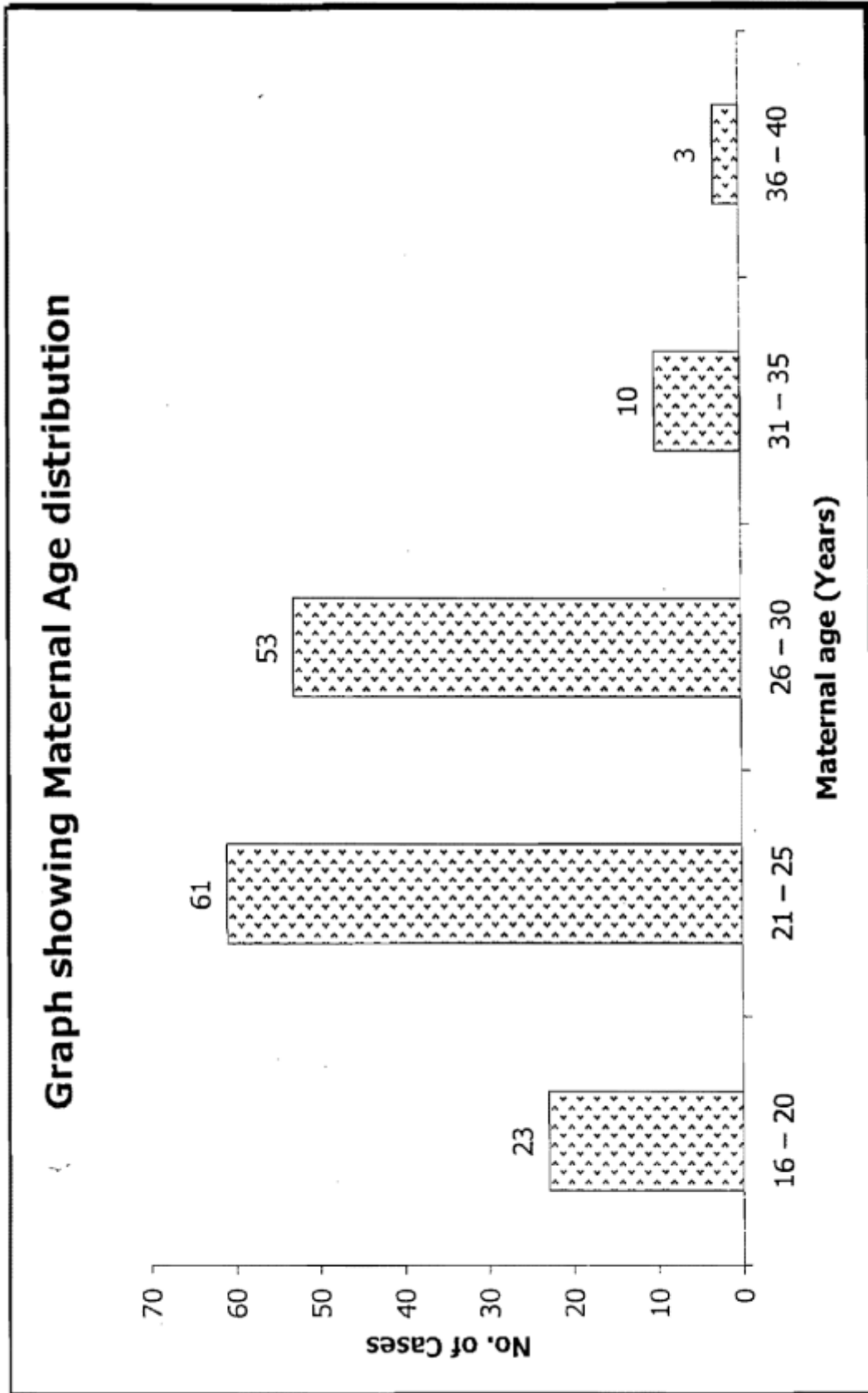
1. Sandra L, Hagen Ansert “Sonography of the first trimester pregnancy”. Dgnostic ultrosonogra phy. 4th Edition, mosby. 1995 Vol II 883.
2. Peter W Callen, “The Obstetric ultrasound examiantion”. Ultrasound in obstetrics and gynecology, 4th Edition W.B saunders company, Londor. 1-17, 2000.
3. Ronald L Eisenberg, “Obstetrical and gynecological Radiology”. Radiology, an illustrated history. Mosby 1992, 355-358.
4. Carol M Rumack et. Al “The placenta” Diagnostic ultrosand, 1st Edition, mosby vol II, 1991, 935.

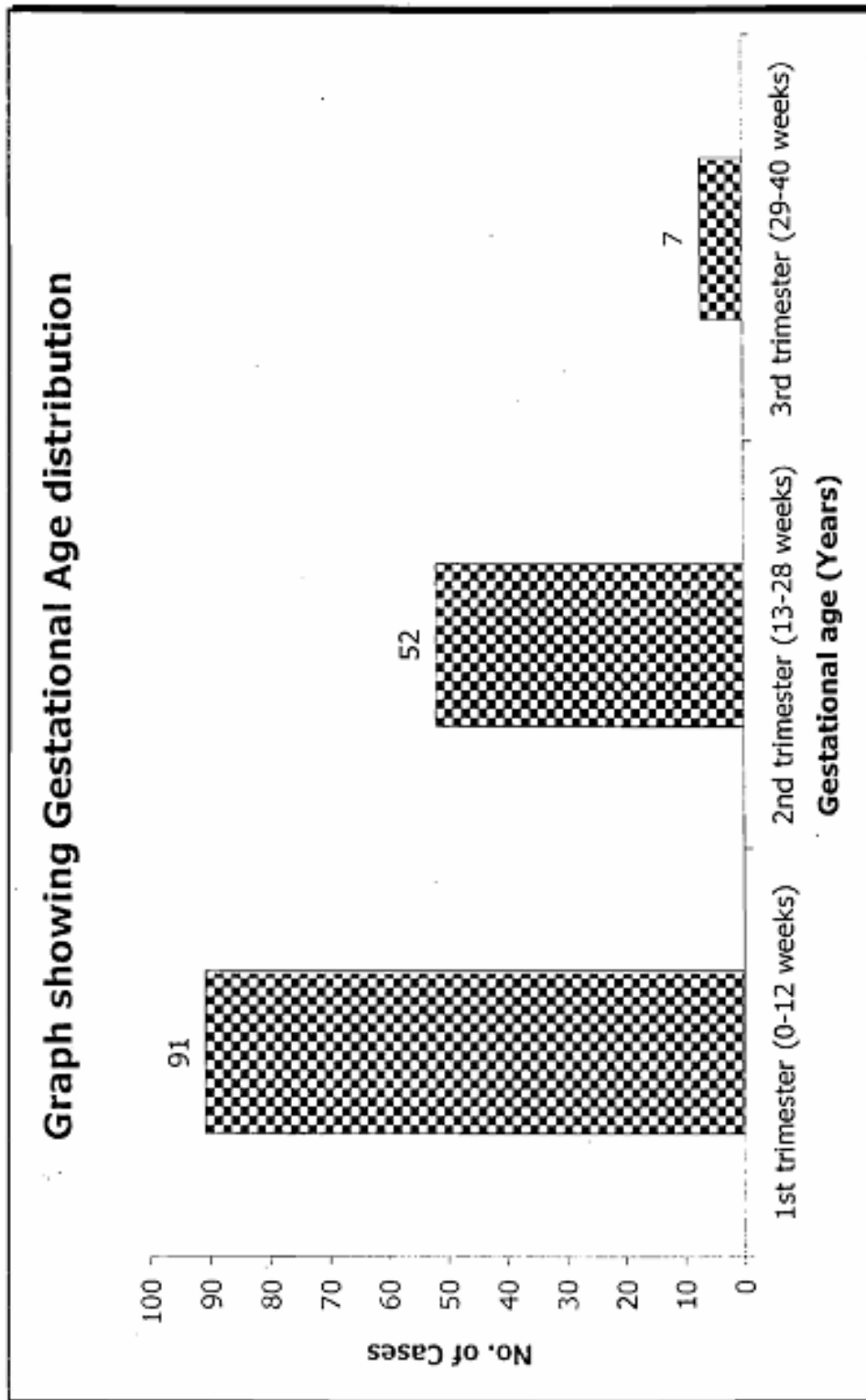
ORIGINAL ARTICLE

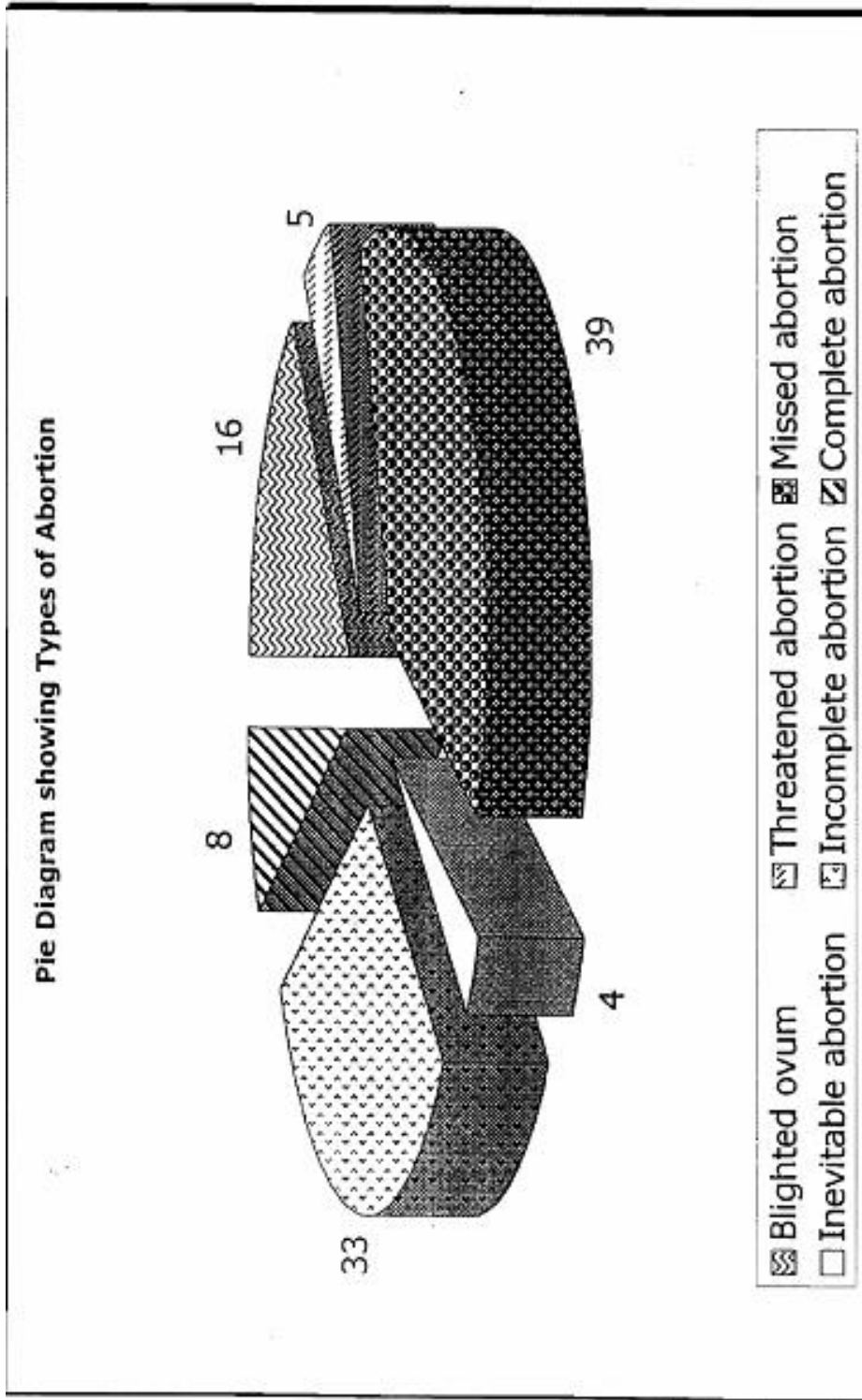
5. Dutta DC, 'diagnosis of pregnancy", Textbook of Obstetrics, New Central Book Agency, Calcutta, 5th Edition, 66-77.
6. Duttà DC, 'Hemorrhage in early pregnancy", Textbook of Obstetrics, New Central Book Agency, Calcutta, Edition, 2001: 175.
7. Roger C Sanders, 'First trimester bleeding", Clinical Sonography, 3rd Edition, Upplincott, 1998: 76-84.
8. Robert D Harris and Roberta D Alexander, "Ultrasound of placenta and umbilical cord", Ultrasound in Obstetrics & Gynecology, Peter W Callen, 4th Edition, WB Saunders Co., 2000; 597-624.
9. Naumoff P et al "ultrasonography of partial Hydatidiform mole". Radiological society of North America. 1981, vol40, 467-470.
10. Deborah Levine, "Ectopic pregnancy", Ultrasound in Obstetrics & Gynecology, Peter W Callen, 4th Edition, WB Saunders Co., 2000: 924-926.
11. Duff GB et al, 'A study of investigations used to predict outcome of pregnancy after the abortion", Br. J. of Obstetrics & Gynecology, 1980; 87: 194-198.
12. Robinson HP, 'Sonar in the management of abortion", Br. J. of Obstetrics & Gynecology, 1972; 79: 90.
13. Trilolo O et al, 'Spontaneous abortions in advanced maternal age", Minerva-Gynecol, 1990; 42: 345.
14. Hamalton RA et al, 'The management of bleeding in early pregnancy", J. Am. Med. Assoc. 1991; 265: 18-19.
15. Gerds E, 'Ultrasound diagnosis in abortion of one twin. The vanishing twin phenomenon. Tidsskr-Nor-Loegeforel, 1989; 20: 2328-3329.

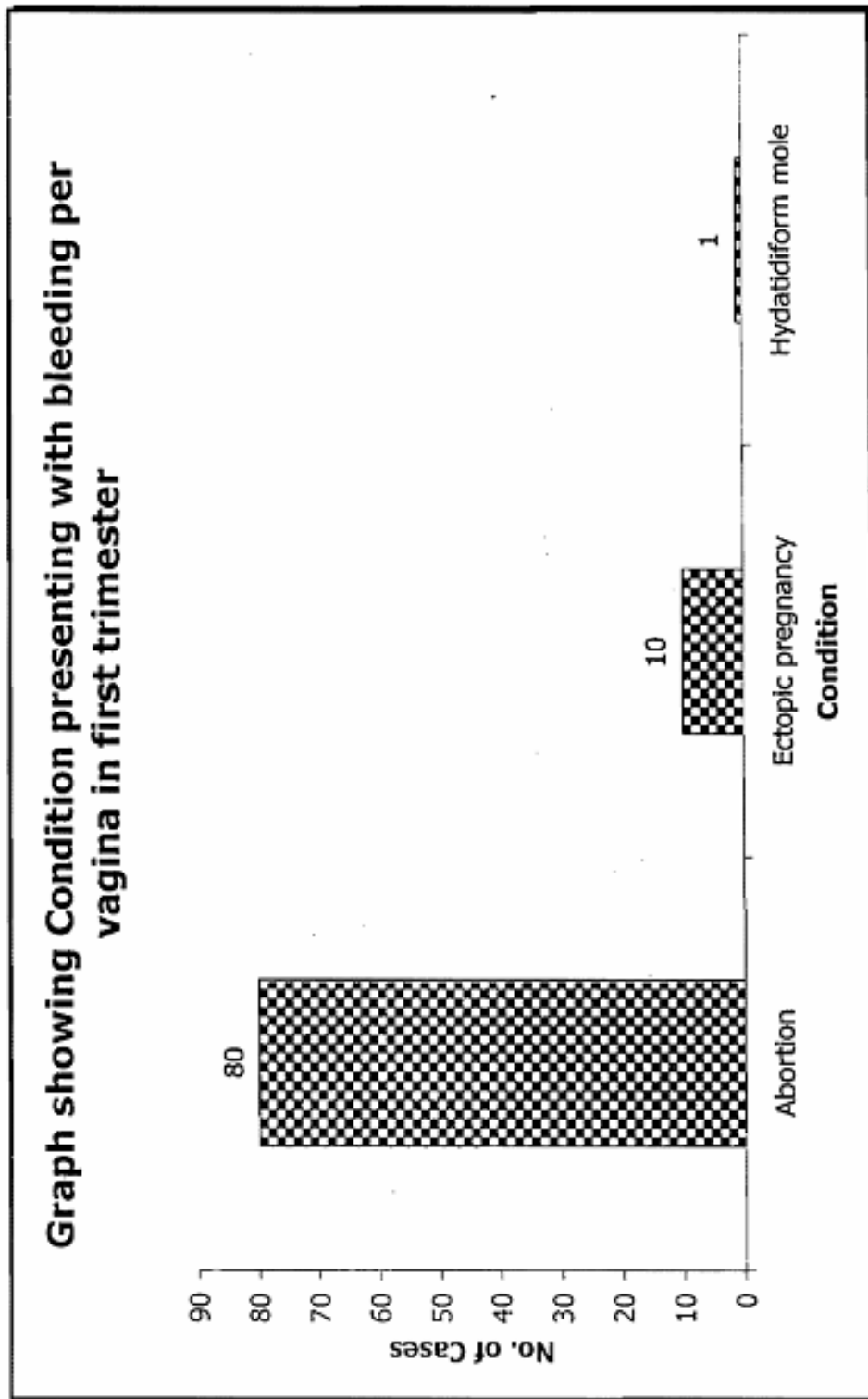
ORIGINAL ARTICLE

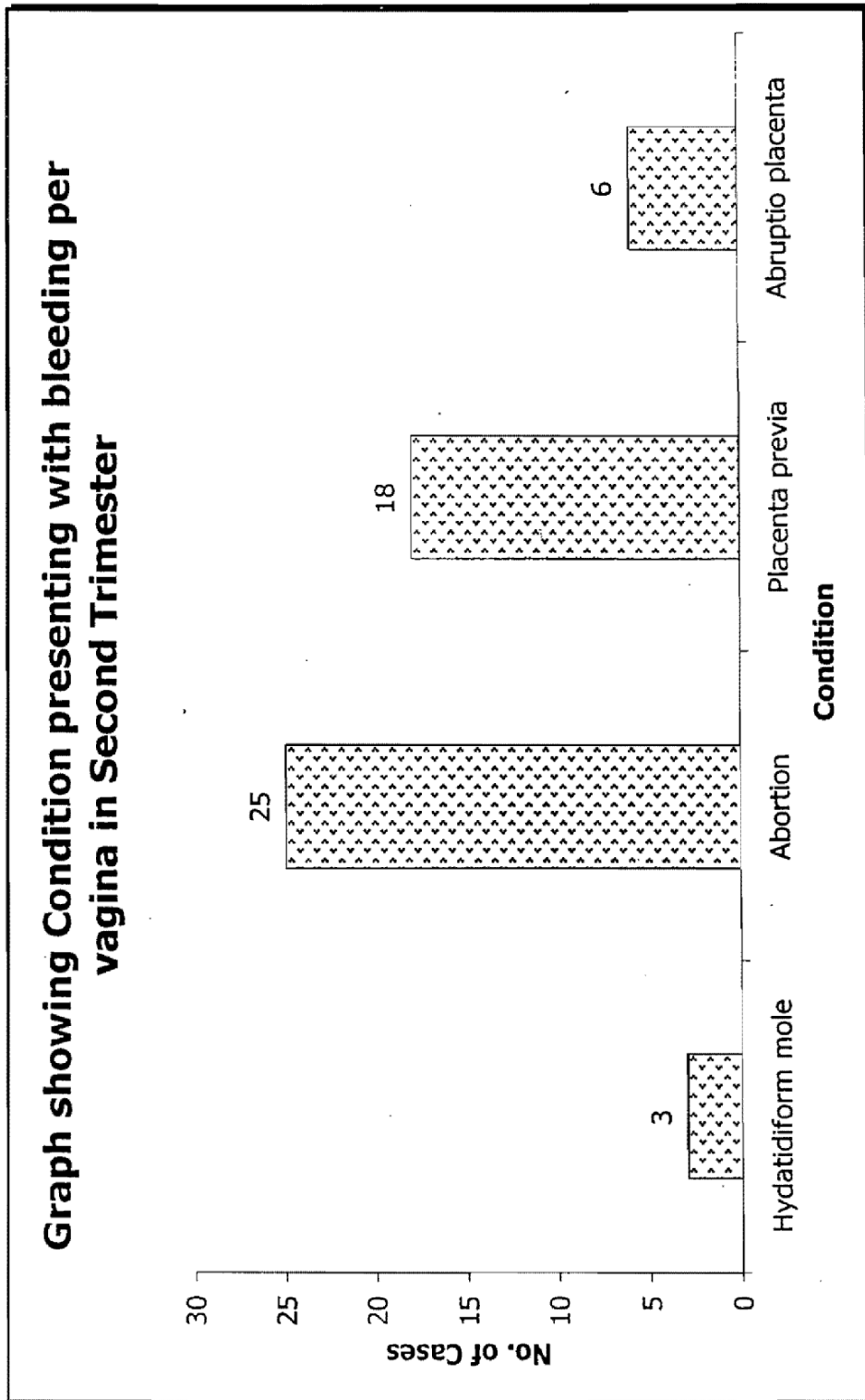


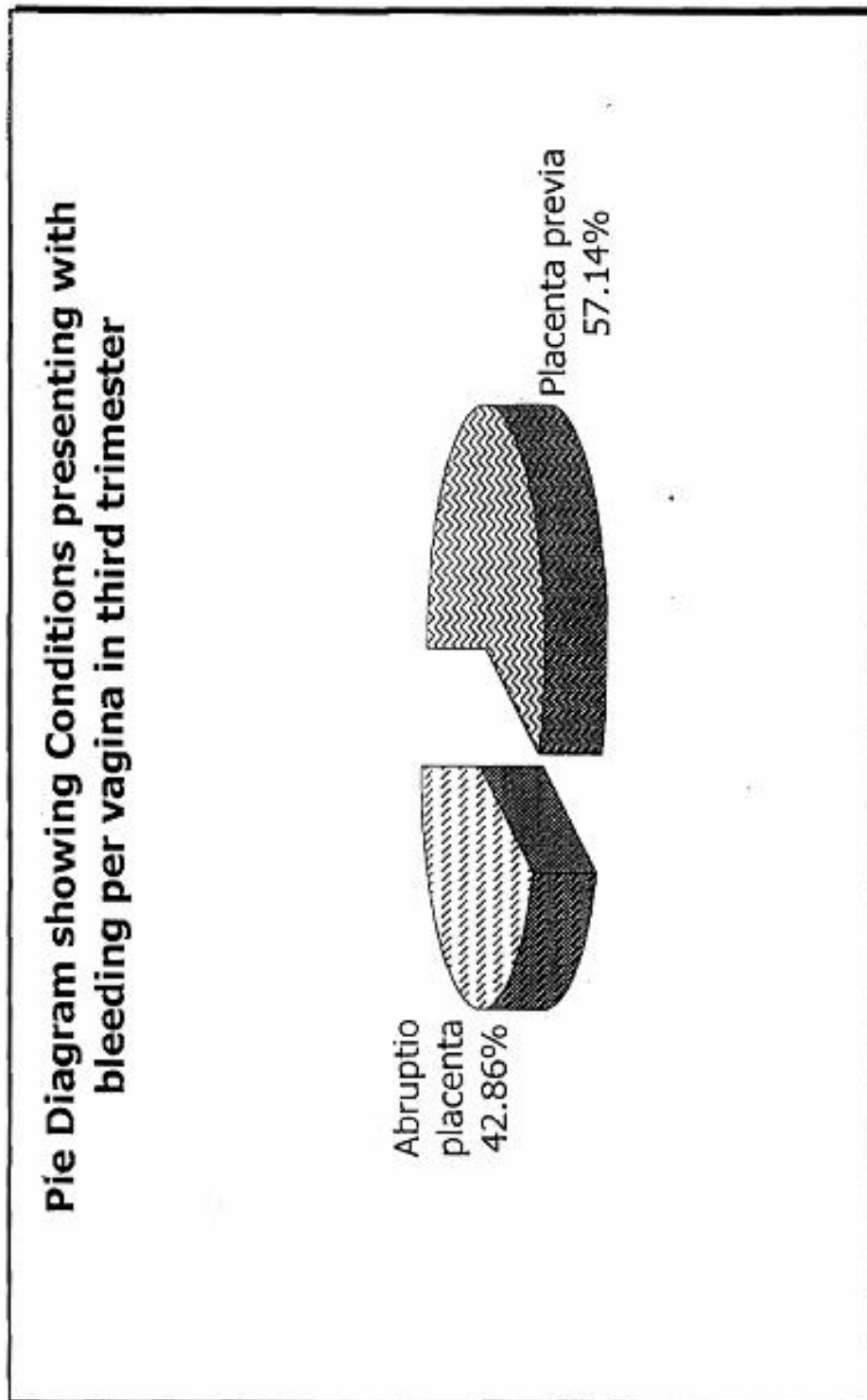


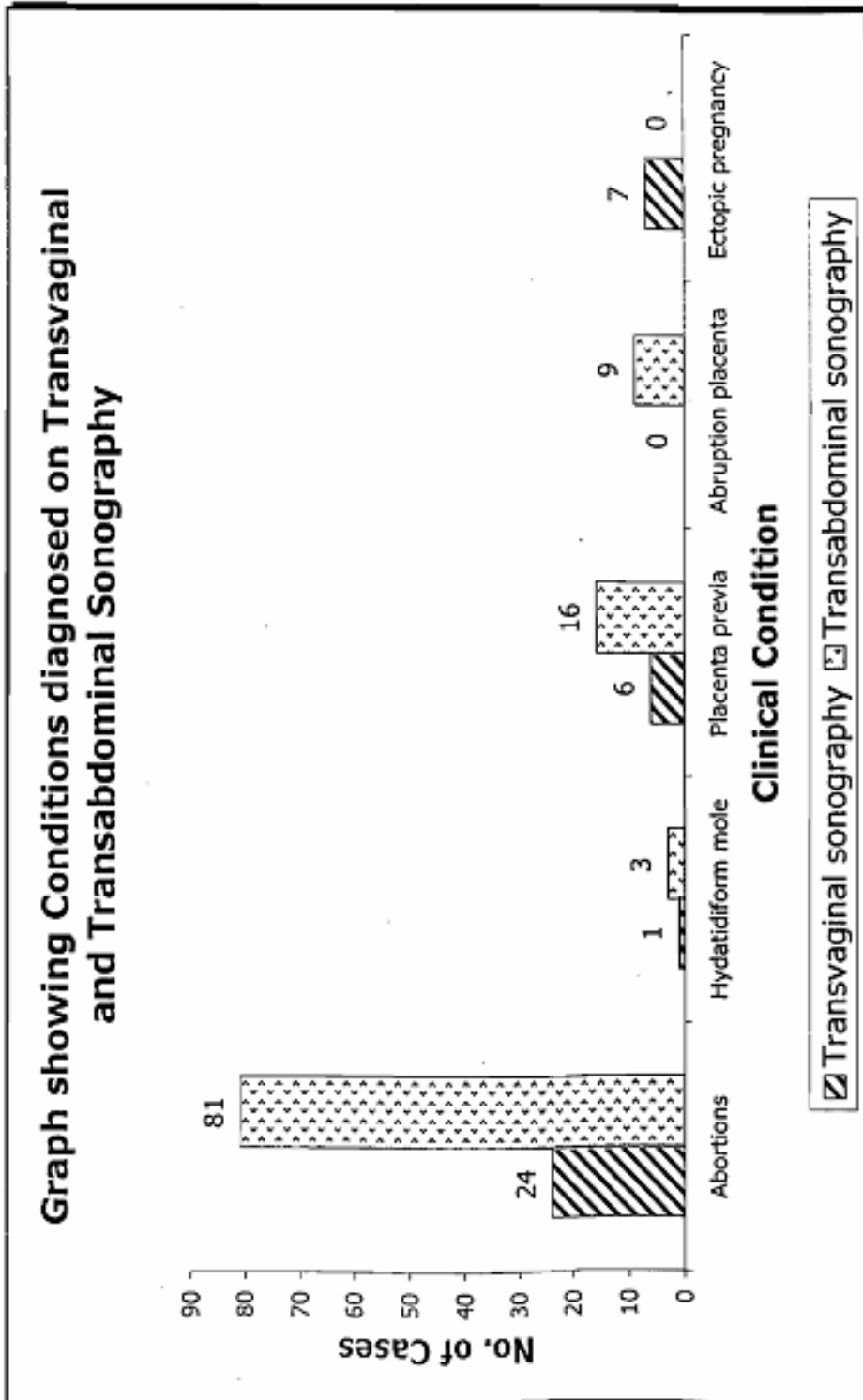




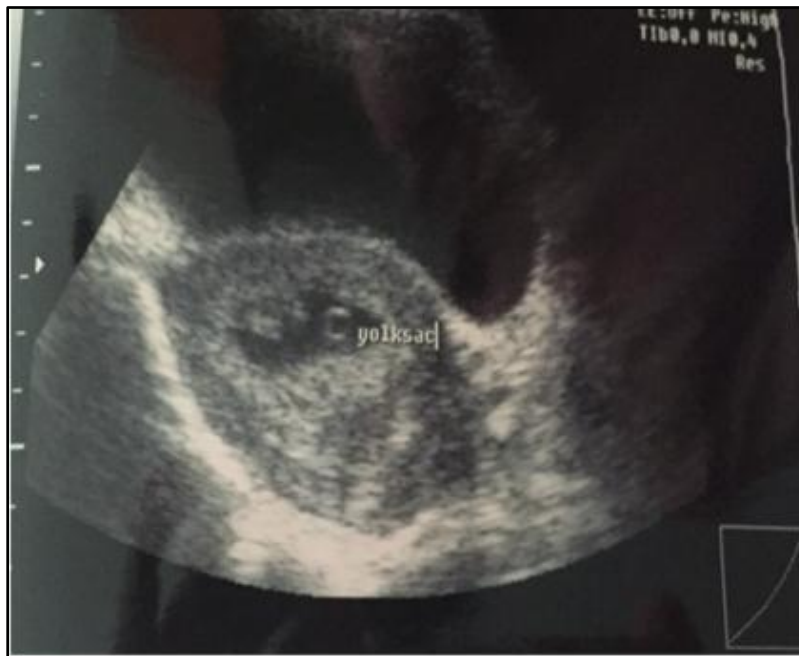




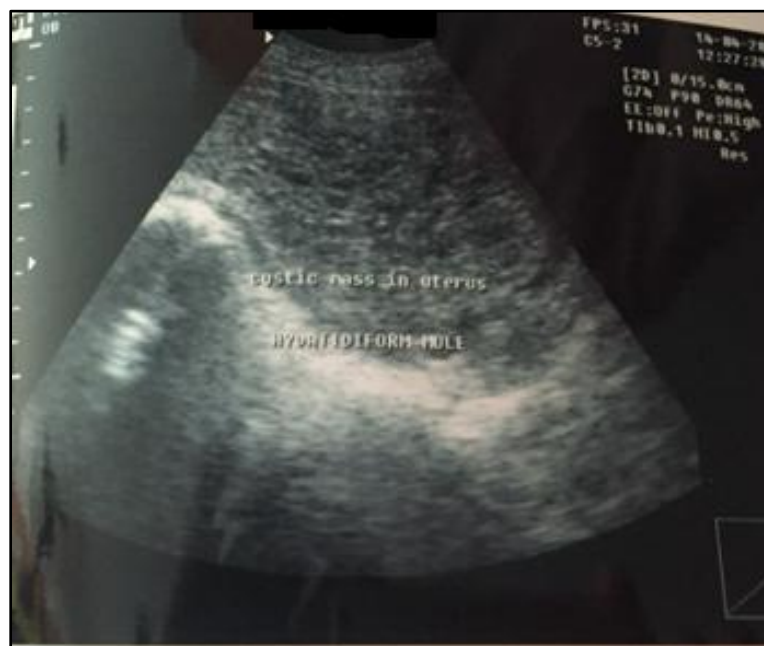


ORIGINAL ARTICLE

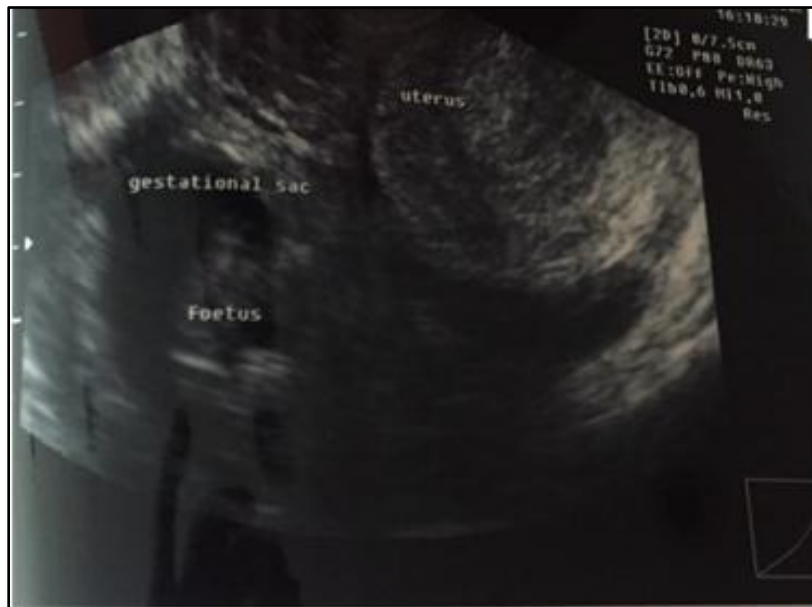

MISSED ABORTION: A NORMAL GESTATIONAL SAC WITH FETAL POLE OF 8 WEEKS. NO FETAL CARDIAC ACTIVITY WAS DETECTED.

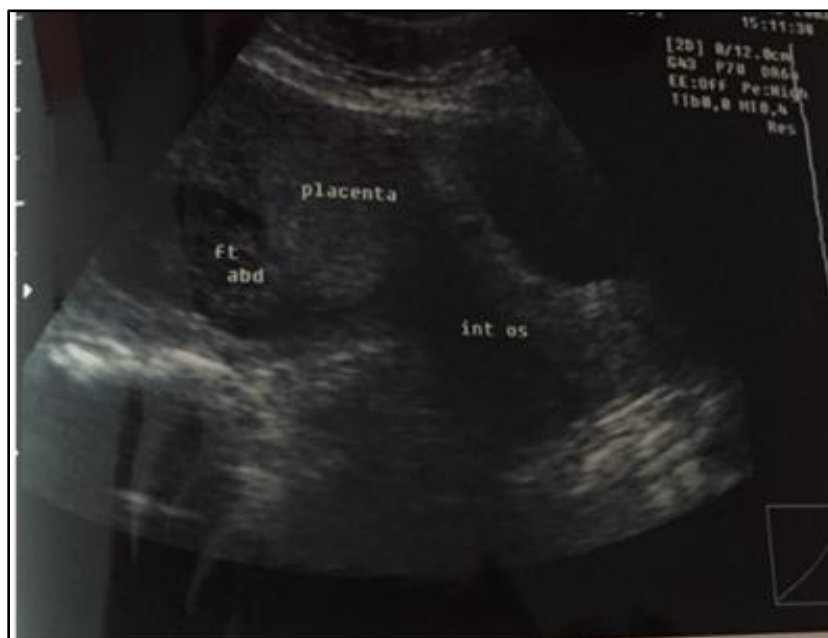

MOLAR PREGNANCY: UTERINE CAVITY IS FILLED WITH ECHOGENIC MATERIAL WITH CYSTIC AREA IN BETWEEN. PLACENTA OR FETAL POLE IS NOT DETECTED.

ORIGINAL ARTICLE

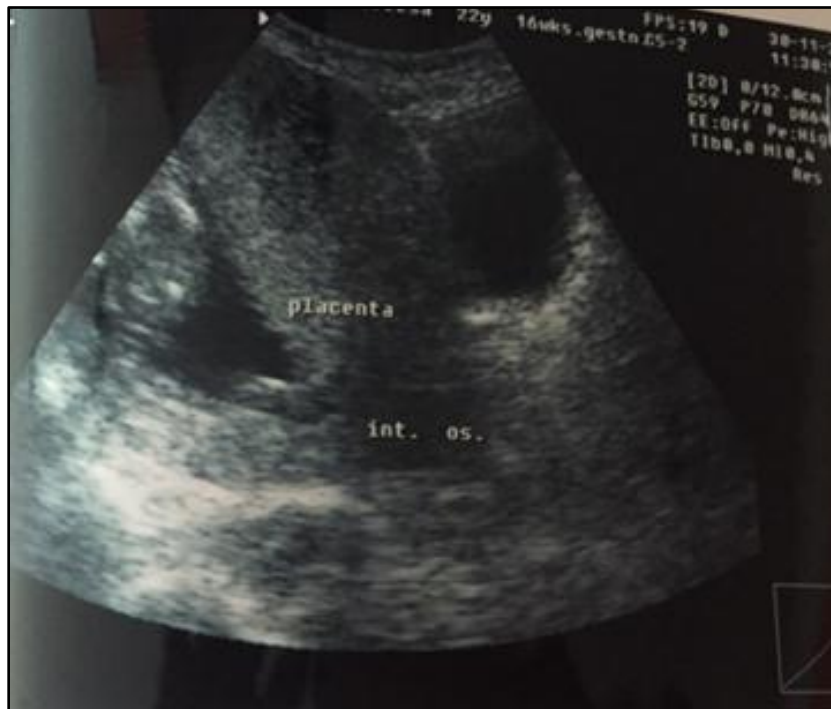

LIVE ECTOPIC PREGNANCY: GESTATIONAL SCA WITH FETAL POLE EVIDENT IN RIGHT ADNEXA. FETAL CARDIAC ACTIVITY WAS DEMONSTRATED BY TRANS VAGINAL PROBE.

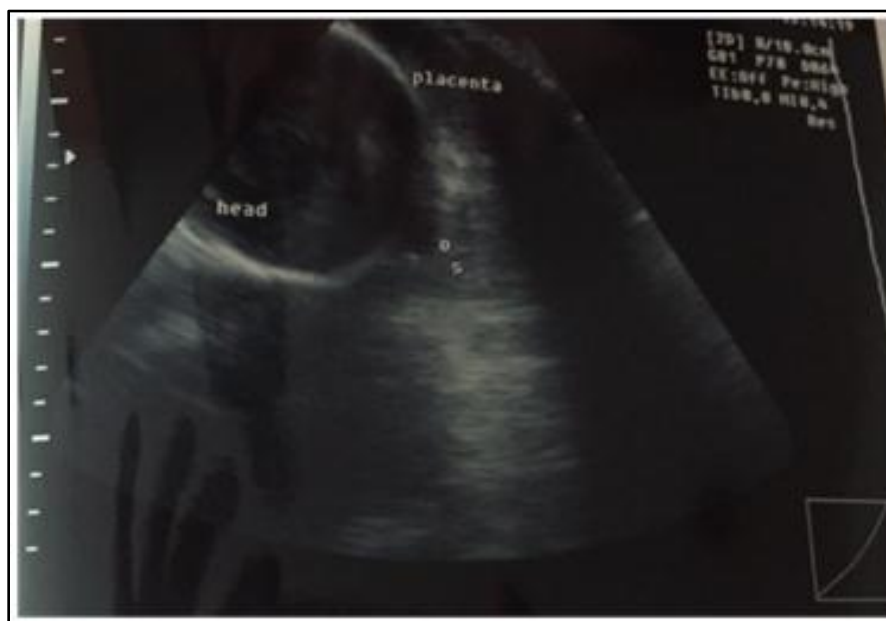

MARGINAL PLACENTA PREVIA: PLACENTAL MARGIN ENCRUCHING THE TIP OF INTERNAL OS IN EARLY PREGNANCY.

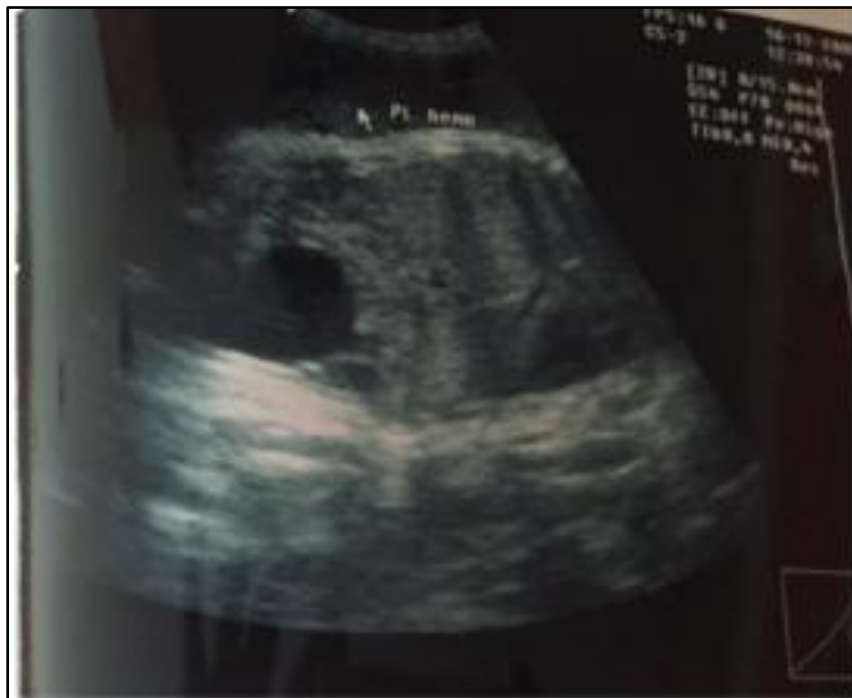ORIGINAL ARTICLE



MARGINAL PLACENTA PREVIA: PLACENTAL MARGIN ENCROCHING THE TIP OF INTERNAL OS IN PREGNANCY 16 WEEKS.



MARGINAL PLACENTA PREVIA: PLACENTAL MARGIN ENCROCHING THE TIP OF INTERNAL OS IN PREGNANCY OF 34 WEEKS.



ABRUPTIO PLACENTA: PLACENTAL SEPERATION WITH RETROPLACENTAL HEMATOMA DETECTED ON TRANS ABDOMENAL SCAN IN PREGNANCY OF 35 WEEKS.

AUTHORS:

1. Amit C. Shah
2. Tushar Patil

PARTICULARS OF CONTRIBUTORS:

1. Assistant Professor, Department of Radiology, Bidar Institute of Medical Sciences, Bidar, Karnataka.
2. Consultant Radiologist, Department of Radiology, Chitrlekha Diagnostic Centre, Doctors Lane Nanded, Maharashtra.

NAME ADDRESS EMAIL ID OF THE CORRESPONDING AUTHOR:

Dr. Amit C. Shah,
8-9-218/15,
Guru Nanak Layout,
Bidar-585401.
Email: docacs@gmail.com

Date of Submission: 11/12/2014.
Date of Peer Review: 12/12/2014.
Date of Acceptance: 15/12/2014.
Date of Publishing: 19/12/2014.